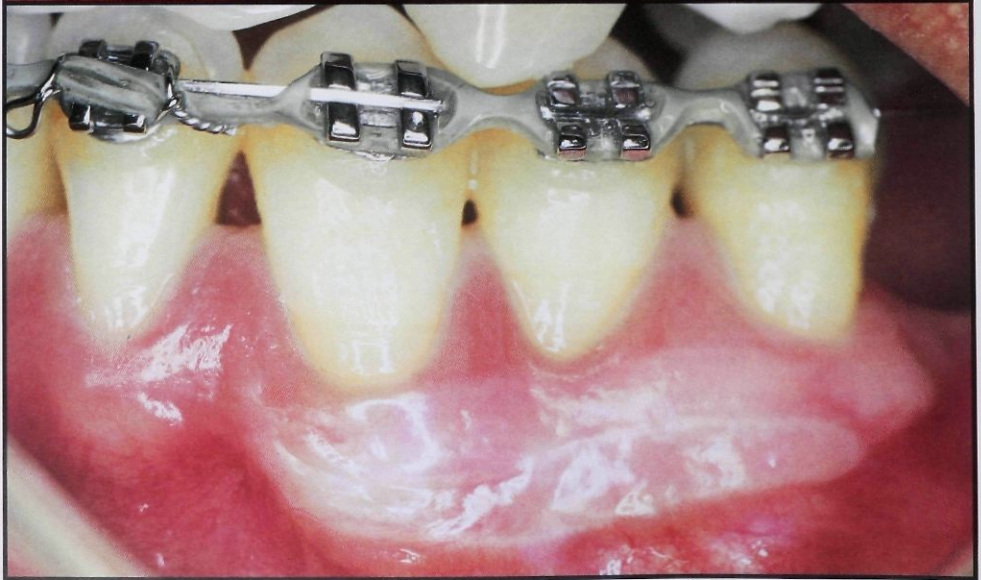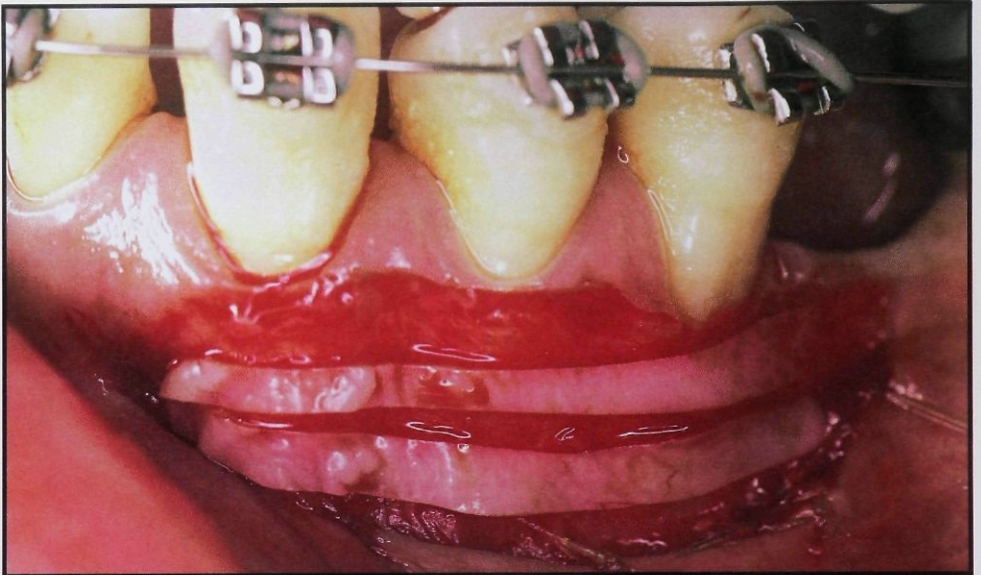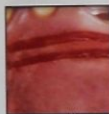


## The Strip Gingival Autograft Technique



Thomas J. Han, DDS, MS\*  
Henry H. Takei, DDS, MS, FACD\*  
Femin A. Carranza, Jr, Dr Odont,  
FACD\*

### Abstract

*In keeping with the concept of rapid epithelialization of close wound edges, the strip technique was developed to maximize the area of gingival grafting with less trauma to the donor site or the recipient site. An incision is made and a partial-thickness flap is reflected so that stable periosteum is left. The apical mucosal border of the recipient site is sutured to the periosteum. Donor tissues are obtained in 2-mm-wide strips, transferred to the recipient site, and sutured. Dry foil and surgical packing are used to stabilize and protect the site during healing. The donor site is rapidly epithelialized (within 10 days) and produces minimal patient discomfort. (Int J Periodont Rest Dent 1993;13:181-187.)*

The use of free gingival autografts to widen the attached gingiva is considered a predictable surgical procedure and the technique has been extensively used since it was first described by Bjorn<sup>1</sup> in 1963. Although the need for such a procedure has been questioned on the basis that areas with minimal attached gingiva can be maintained,<sup>2-4</sup> it is generally agreed that gingival grafting procedures are still indicated in areas where the likelihood of progressive gingival recession is present. Some of the areas where progressive gingival recession can be found and a gingival graft can be indicated to prevent further recession are restored teeth with subgingival margins, around rotated or displaced teeth, and where recession is accompanied by persistent gingival inflammation.

The conventional free gingival graft technique consists of obtaining keratinized tissue, usually from the palate, and transferring it to the prepared gingival recipient site.<sup>5</sup> The size of the donor tissue generally depends on the number of teeth involved and the extension of the recipient site.

When the procedure is two or three teeth wide, the donor site becomes a large open wound that is difficult to protect and often results in post-operative pain and bleeding. The various techniques to protect and cover the donor site have their advantages and disadvantages,<sup>6</sup> but, regardless of the procedure used, the process of healing by secondary intention of a large donor site is painfully slow.

Techniques such as the connective tissue graft and the accordion technique facilitate healing of donor sites. The connective tissue graft leaves the donor site covered by an intact flap and transfers only the connective tissue.<sup>7</sup> However, the removal of connective tissue can be time-consuming and technique-dependent, and the size that can be obtained may be too small for the recipient site.

\* University of California at Los Angeles  
School of Dentistry  
Center for the Health Sciences  
Los Angeles, California 90024

The accordion technique decreases the size of donor tissue needed by expanding the graft with intercalated incisions.<sup>8</sup> With this technique the donor site, although smaller, still takes time to heal because it proceeds by secondary intention. The wound is initially covered by a blood clot followed by the migration of epithelial cells from the wound edges. Although the maturation and organization of the connective tissue continue well after epithelialization has occurred, the rate of healing of the donor site depends on the size of the wound. If the epithelial wound edges are close, the healing should be rapid because epithelial cells will have a shorter distance to migrate to cover the wound.

In keeping with this concept of rapid epithelialization of close wound edges, the strip technique was developed to maximize the area of gingival grafting and inflict less trauma to the donor sites. This procedure is designed to widen the attached gingiva and not to cover denuded root surfaces caused by gingival recession. In essence, large areas of attached, keratinized tissue can be created with minimal discomfort to the patient.

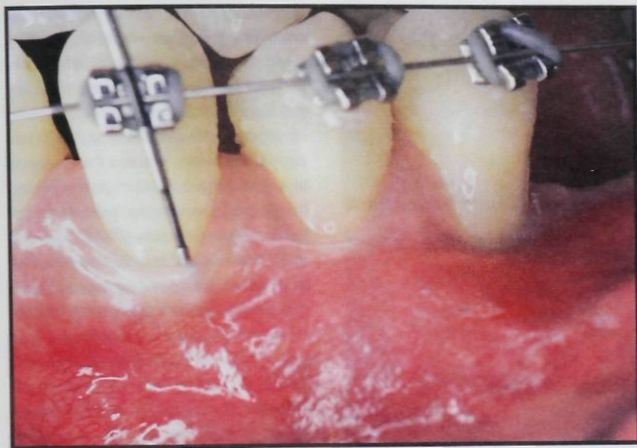
## Surgical technique

### *Recipient site preparation*

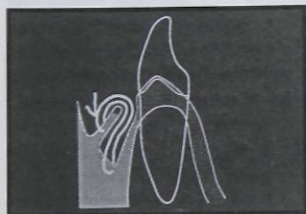
As with any periodontal surgery, a thorough phase I therapy is essential to obtain healthy gingival tissue. The initial incision for the preparation of the recipient site is made coronal to the mucogingival junction. Because of the lack of attached gingiva of the teeth needing surgery, the initial incision is often, on radicular surfaces, at the crest of the gingiva (Fig 1). The length of the incision is determined by the number of teeth involved and should extend at least to the mesial line angle of the next tooth on each side. The incision is terminated with a slight apical curvature to provide easier release of the mucosal tissue.

A partial-thickness flap is then reflected in such a way that a firm stable periosteum is left on the recipient site. Loose connective tissue left on the recipient site will result in keratinized tissue that is mobile.

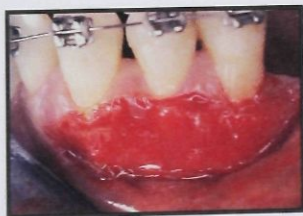
The apical mucosal border of the recipient site is sutured down to the periosteum. This is accomplished with a thin gut suture in the following way. A vertical mattress suture is placed in the mucosal edge of the incision. The suture is continued with a horizontal mattress in the periosteal tissue at the apical end of the recipient site before a knot is tied (Fig 2). The entrance and exit of both the mattress sutures are approximately 2 to 3 mm apart. The Y- or V-shape pattern of the suture as it extends from the vertical to the horizontal mattress suture allows maximum retention of the loose mucosal wound edge against the fixed periosteum (Fig 3).



*Fig 1 Presurgical photograph of an orthodontic patient with the potential for mucogingival problems.*



*Fig 2 Diagram of the suturing of the recipient site.*



*Fig 3 Prepared recipient site.*

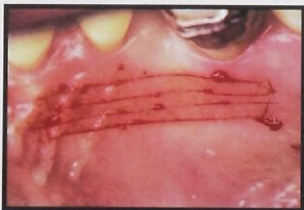

Fig 4 Outline of donor site.

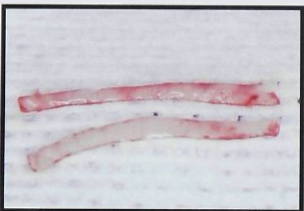


Fig 5 Donor strips removed from palate.

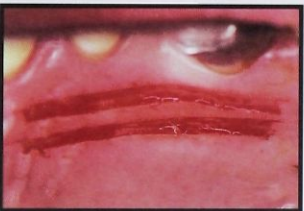

Fig 6 Donor site after strip removal.

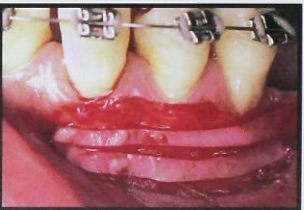

Fig 7 Recipient site with donor strips in place.

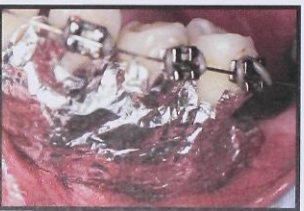

Fig 8 Recipient site with dry foil in place.

Managing the recipient site in this manner provides several advantages. It delineates the recipient site, making it easier to manage flaps during surgery. It minimizes the formation of a pouchlike area during the healing phase. Also, suturing the mucosal tissue to the periosteum at the apical borders of the recipient site provides hemostasis. Because the donor tissues are not sutured to the recipient bed, excessive bleeding makes it very difficult to stabilize the donor tissues.

#### *Donor site*

After the recipient site has been prepared, the length of the area to be covered is measured and the donor site is approached. Donor tissues are obtained, usually from the ipsilateral palate, in strips. Two strips as long as the recipient bed are obtained. To facilitate healing, there should be intact palatal tissue between the two donor strips (Fig 4). These strips are approximately 2 mm wide and should be as thin as possible (about 0.50 to 0.75 mm thick) (Fig 5). The donor sites are left without sutures or dressing (Fig 6). As long as the strips are thin, postoperative bleeding and pain are not a problem.

#### *Transfer of strip grafts*

The donor strips are then transferred to the recipient site. The epithelial side should be noted because it is difficult to recognize the difference. The strips are placed with their connective tissue side against the recipient bed, one in a coronal position and the other in a more apical position. With adequate hemostasis and strips of proper thickness, the tissue will adapt and adhere to the recipient site (Fig 7).

Gut mattress sutures from the apical portion of the recipient site to the coronal portion may be used to keep the strips stabilized during the healing period, but the best way to stabilize and protect the donor tissue and recipient site is to use dry foil and surgical packing. Dry foil is trimmed to fit into the apical border of the recipient site. The coronal portion of the foil is serrated to facilitate its adaptation to the interproximal area. The sticky surface of the foil keeps the strips against the recipient site, and it prevents the dressing from dislodging the graft tissue (Fig 8). The periodontal dressing is placed over the foil while it is still soft so that it can be molded by the lips and vestibule. The dressing should be pressed into interproximal areas to provide retention (Fig 9).

#### Postoperative care

The initial postoperative visit is 7 to 10 days after surgery. The dressing usually stays on for that duration, but if it does come loose before, the patient should not brush the area or chew on the side of surgery. In 1 week the recipient site shows sloughing of the surface keratin, with incomplete epithelialization of the wound (Fig 10). The site need not be cleansed, and a chlorhexidine oral rinse is prescribed for 1 week. The patient can return to normal tooth-brushing in 2 weeks. Discomfort associated with the recipient site is usually minimal, despite its unhealed appearance 1 or 2 weeks postsurgery.

The donor site is rapidly epithelialized (usually within 10 days), and, unlike the donor site of conventional free gingival autografts, it produces minimal discomfort to the patient (Fig 11).

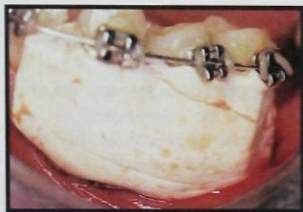


Fig 9 Recipient site with soft periodontal dressing in place.

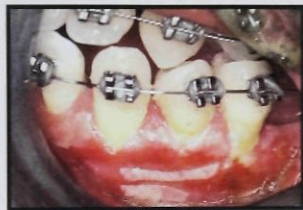

Fig 10 One-week postoperative view after removal of the periodontal dressing.

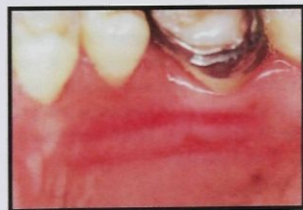


Fig 11 One-week postoperative healing of donor site.

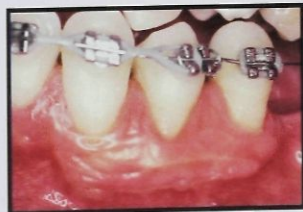

Fig 12 Four-month postoperative view.

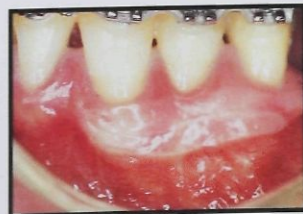


Fig 13 Twenty-two-month postoperative view.

The recipient site shows excellent healing and increased keratinized attached gingiva (Figs 12 and 13). The area covered by the new attached tissue is not homogeneous and shows the remnants of the strips' contours, but the amount and quality of new keratinized attached tissue are similar to those that would have been obtained with a solid, wide piece of tissue, which would also have produced a troublesome postoperative period in the donor site.

#### Discussion

Frequently, especially in the mandibular arch, there is a generalized mucogingival problem with a potential progressive recession. A conventional free gingival autograft technique of this magnitude often leaves a very painful donor site that requires special procedures to decrease the patient's discomfort, which can last up to 3 or 4 weeks.

The advantage of the strip technique is that it creates minimal trauma to the donor site, resulting in less bleeding and discomfort. Studies on wound healing<sup>9</sup> indicate that epithelial cells migrate from adjacent epithelialized tissue to cover the open wound. Therefore, if the donor tissues are removed in strips, regardless of the length or number of the strips, they should heal rapidly because the epithelium has a shorter distance to travel.

With this technique, extensive mucogingival problems can be treated in one appointment. This technique consistently provides a wide zone of healthy, keratinized attached gingiva and prevents further gingival recession.

It has been clinically observed that the total amount of keratinized attached gingiva gained with this technique is roughly equivalent to the total widths of the strips placed on the recipient site. Regardless of the width of the recipient site or the way in which the strips are positioned on the recipient bed, within 3 months, condensing of the strips can be observed with the consequent coronal migration of the mucogingival junction to a width similar to the total width of the donor strips. This observation confirms the results of some of the postoperative studies on alteration of vestibular depth.<sup>10</sup>

---

## References

---

1. Bjorn H. Free transplantation of gingiva propria. *Sverige Tandlakarforb Tidn* 1963;22:684.
2. Dorfman HS, Kennedy JE, Bird WC. Longitudinal evaluation of free autogenous gingival grafts. *J Clin Periodontol* 1980;7:316.
3. Dorfman HS, Kennedy JE, Bird WC. Longitudinal evaluation of free autogenous gingival grafts. A four year report. *J Periodontol* 1982;53:349.
4. Miyasato M, Crigger M, Egelberg J. Gingival conditions in areas of minimal and appreciable width of keratinized gingiva. *J Clin Periodontol* 1977;4:200.
5. Carranza FA, Jr. *Glickman's Clinical Periodontology*, ed 7. Philadelphia: Saunders, 1990.
6. Farnoush A. Technique for the protection and coverage of the donor sites in free soft tissue grafts. *J Periodontol* 1979;49:403.
7. Edel A. Clinical evaluation of free connective tissue grafts used to increase the width of keratinized gingiva. *J Clin Periodontol* 1974;1:185.
8. Rateitschak KH, Rateitschak EM, Wolf HF, Hassell TM. *Color Atlas of Periodontology*, ed 2. New York: Thieme, 1989.
9. Oliver R, Loe H, Karring T. Microscopic evaluation of the healing and revascularization of free gingival grafts. *J Periodont Res* 1968;3:84-95.
10. Bohannon HM. Studies in the alteration of vestibular depth. II. Periosteum retention. *J Periodontol* 1962;33:354.



Copyright of International Journal of Periodontics & Restorative Dentistry is the property of Quintessence Publishing Company Inc. and its content may not be copied or emailed to multiple sites or posted to a listserv without the copyright holder's express written permission. However, users may print, download, or email articles for individual use.