

Marco Ronda  
 Alberto Rebaudi  
 Lucio Torelli  
 Claudio Stacchi

## Expanded vs. dense polytetrafluoroethylene membranes in vertical ridge augmentation around dental implants: a prospective randomized controlled clinical trial

### Authors' affiliations:

Marco Ronda, Alberto Rebaudi, Private Practice, Genova, Italy

Lucio Torelli, Department of Mathematics and Informatics, University of Trieste, Trieste, Italy

Claudio Stacchi, Department of Medical, Surgical and Health Sciences, University of Trieste, Trieste, Italy

### Corresponding author:

Marco Ronda, MD, DDS  
 Private Practice  
 Piazza Brignole 3/8, 16122 Genova, Italy  
 Tel.: +39 010 583435  
 Fax: +39 010 583435  
 e-mail: mronda@panet.it

**Key words:** biomaterials, bone regeneration, clinical research, clinical trials, guided tissue regeneration

### Abstract

**Objective:** This prospective randomized controlled trial was designed to test the performance of titanium-reinforced dense polytetrafluoroethylene (d-PTFE) membrane vs. titanium-reinforced expanded polytetrafluoroethylene (e-PTFE) membrane in achieving vertical bone regeneration, both associated with a composite grafting material.

**Material and methods:** The study enrolled 23 patients requiring bone augmentation with guided bone regeneration (GBR) procedures for placing implants in atrophic posterior mandibles (available bone height <7 mm). Implants were inserted and left to protrude from the bone level to achieve the programmed amount of vertical regeneration. Defects were filled with a composite bone graft (50% autologous bone and 50% mineralized bone allograft) and randomly covered with either an e-PTFE membrane (control) or a d-PTFE membrane (test). Membrane removal was performed after 6 months, and changes in bone height were recorded.

**Results:** Seventy-eight implants were inserted in 26 mandibular sites contextually to vertical ridge augmentation procedures. The healing period was uneventful in all sites, and the vertical defects were satisfactorily filled with a newly formed hard tissue. Mean defect fill after 6 months was 5.49 mm (SD  $\pm$  1.58) at test sites and 4.91 mm (SD  $\pm$  1.78) at control sites. The normalized data (percentage changes against baseline) did not show any statistically significant difference between test and control groups ( $P = NS$ ).

**Conclusions:** Based on the data from this study, both d-PTFE and e-PTFE membranes showed identical clinical results in the treatment of vertical bone defects around implants, using the GBR technique. The membrane removal procedure was easier to perform in the d-PTFE group than in the e-PTFE group.

The effectiveness of guided bone regeneration (GBR) with non-resorbable membranes in obtaining vertical regeneration of the alveolar crest has been clinically and histologically documented in many studies (Simion et al. 1994a, 1998; Tinti et al. 1996; Parma-Benfienati et al. 1999). Moreover, the stability of the bone vertically regenerated around dental implants and its favorable response under functional loading have been demonstrated in human subjects (Tinti & Parma-Benfienati 1998; Simion et al. 2001; Zitzmann et al. 2001; Aghaloo & Moy 2008).

In the GBR technique, a membrane is used as a mechanical barrier to create a protected space around the bone defect: The blood clot fills the

space, and osteogenic cells are allowed to colonize the augmentation area without the competition of the overlying soft tissue cells. The fundamental characteristics of barrier membranes in regenerative therapy were defined by Karring et al. (1993) and include biocompatibility, cell occlusion properties, integration by the host tissues, clinical manageability and space-making ability. These requisites are fulfilled by polytetrafluoroethylene (PTFE), a polymer consisting of a carbon backbone covalently bonded to a uniform sheath of fluorine atoms, which can be manipulated and engineered into a variety of forms.

For years, research has been focused mainly on the applications of expanded

### Date:

Accepted 26 February 2013

### To cite this article:

Ronda M, Rebaudi A, Torelli L, Stacchi C. Expanded vs. dense polytetrafluoroethylene membranes in vertical ridge augmentation around dental implants: a prospective randomized controlled clinical trial. *Clin. Oral Impl. Res.* 25, 2014, 859–866  
 doi: 10.1111/clr.12157

polytetrafluoroethylene (e-PTFE) membranes, exploring their potential in horizontal and vertical guided bone regeneration and documenting that their use predictably leads to successful GBR treatment results (Hämmerle & Jung 2003).

A number of biomaterials were clinically compared with e-PTFE, which is considered the gold standard, to establish their validity as an option for vertical GBR treatment (Carpio et al. 2000; Proussaefs et al. 2003; Llambés et al. 2007; Jung et al. 2009). Particularly, dense polytetrafluoroethylene (d-PTFE), a less porous form of polytetrafluoroethylene, has been on the market for many years, and its efficacy has been tested in periodontal regenerative therapy (Lamb et al. 2001; Walters et al. 2003) and in socket preservation procedures (Bartee 1998; Hoffmann et al. 2008; Fotek et al. 2009; Barboza et al. 2010), but d-PTFE has never been compared with e-PTFE in a randomized controlled clinical study employing vertical guided bone regeneration around implants. Therefore, the objective of this clinical investigation was to test whether a GBR procedure performed with a titanium-reinforced e-PTFE membrane would result in a superior amount of vertical bone fill compared with a GBR performed using a titanium-reinforced d-PTFE membrane, both combined with an osteoconductive composite graft. The null hypothesis of this study holds that no difference in vertical bone gain around implants results from performing GBR procedures with either e-PTFE or d-PTFE membranes.

## Material and methods

This study was designed as a prospective randomized controlled clinical trial. All procedures were performed in accordance with the recommendations of the Declaration of Helsinki (2008) for investigations with human subjects. All patients received thorough explanations on the protocol and signed a written informed consent form prior to being enrolled in the trial.

### Study population

Twenty-three consecutive patients needing dental implants in the posterior mandible were enrolled in this study from January 2009 to November 2010. One patient (4.3%) was male and 22 (95.7%) were female, with an age range from 30 to 78 years (mean  $49.6 \pm 11.6$  years). Eight patients were light smokers (34.8%), and 15 were non-smokers (65.2%). The inclusion criterion was a

mandibular partial edentulism (Applegate-Kennedy class I or II), involving the premolar/molar area, associated with the presence of crestal bone height  $<7$  mm coronal to the mandibular canal. General exclusion criteria were acute myocardial infarction within the past 2 months, uncontrolled coagulation disorders, uncontrolled diabetes (glycated hemoglobin  $>7.5$ ), immunosuppressed or immunocompromised patients, radiotherapy to the head/neck district performed within the past 24 months, chemotherapy for treatment of malignant tumors at the time of the surgical procedure, present or past treatment with intravenous bisphosphonates, psychological or psychiatric problems, heavy smoking ( $>10$  cigarettes per day), and alcohol or drug abuse. Local exclusion criterion was the presence of uncontrolled or untreated periodontal disease involving residual dentition. The sites to be treated were randomly assigned to the test or control group by a computer-generated table, which was prepared using a balanced, randomly permuted block approach ([www.randomization.com](http://www.randomization.com)).

### Test and control devices

#### D-polytetrafluoroethylene membrane

The investigational device was a titanium-reinforced, non-resorbable membrane (Cytoplast, Osteogenics Biomedical Inc., Lubbock, TX, USA). This membrane consists of three layers: an outer part of high-density polytetrafluoroethylene with a submicron ( $<0.3 \mu\text{m}$ ) porosity size and a textured surface (Regentex™), an intermediate grade 1 titanium structure, and an inner e-PTFE layer.

#### E-polytetrafluoroethylene membrane

The control device was a titanium-reinforced, non-resorbable membrane (Gore-Tex TR9, W. L. Gore & Associates Inc., Flagstaff, AZ, USA). This membrane consists of a double layer of porous expanded PTFE. The first layer has an open microstructure portion ( $100\text{--}300 \mu\text{m}$  porosity), and the second layer has an occlusive portion ( $<8 \mu\text{m}$  porosity).

#### Bone graft

The material grafted under the membranes was a composite graft with a 50 : 50 proportion of autologous bone and mineralized bone allograft in granules (cortical  $250\text{--}1000 \mu\text{m}$  and spongy  $1000$  and  $2000 \mu\text{m}$ ) (Puros, Zimmer Dental, Carlsbad, CA, USA).

### Clinical procedures

At the initial visit, all subjects underwent a clinical and occlusal examination, periapical

and panoramic radiographs, and impressions for study models. Then, a prosthetic evaluation with diagnostic waxing was carried out, and a computed tomography (CT) scan with a radio-opaque template was performed to plan implant surgery. A single operator (M.R.) performed all the surgeries consecutively to reduce surgical variability.

Presurgical medication consisted of two tablets of amoxicillin/clavulanate potassium ( $875 + 125$  mg) (Augmentin, GlaxoSmithKline, Brentford, UK) for each patient 1 h prior to the surgery and chlorhexidine mouthwash 0.2% (Corsodyl, GlaxoSmithKline, Brentford, UK) for 60 s.

Each patient was draped to guarantee maximum asepsis, and the perioral skin was disinfected using iodopovidone 10% (Betadine, Viatris, Milano, Italy).

Under local anesthesia (4% articaine with epinephrine 1 : 100,000; Septanest, Septodont, Saint Maur des Fossés, France), a full-thickness crestal incision was performed in the keratinized tissue, from the distal surface of the more distal tooth to the mandibular ramus, finishing with a releasing incision on its buccal surface. If a tooth posterior to the augmentation area was still present, the incision continued 5 mm distally from it before performing the releasing incision. The flap design continued mesially on both buccal and lingual sides. Buccally, it involved two teeth before finishing with a vertical hockey stick-releasing incision. Lingually, it involved one tooth until the gingival zenith and then continued horizontally in mesial direction for 1 cm in the keratinized tissue. Then, a full-thickness vestibular flap was elevated, and, after isolating the mental nerve, it was released with a longitudinal periosteal incision, avoiding the mental foramen area. On the lingual side, a full-thickness mucoperiosteal flap was elevated until reaching the mylohyoid line and then passivated by detaching the insertion of the mylohyoid muscle from the inner part of the flap, as described by Ronda & Stacchi (2011).

The implant site preparations were made using twist drills and finalized in the last portion over the mandibular canal with piezoelectric inserts (Piezosurgery, Mectron, Carasco, Italy) to limit the risk of mandibular nerve damage (Schäeren et al. 2008) and to take advantage of the possible benefits of ultrasonic site preparation (Preti et al. 2007; Stacchi et al. 2013). The fixtures were then placed (Spline Twist and Tapered Screw-Vent, Zimmer Dental, Carlsbad, CA, USA) and left protruding from the alveolar crest for the programmed amount of vertical regeneration.

Multiple perforations of the cortical bone were made with an OP5 piezoelectric insert stimulate bone bleeding and migration of osteoprogenitor cells from the marrow spaces (Frost 1983). At this point, the randomization envelope was opened, and the assigned treatment was revealed to the surgeon: Titanium-reinforced e-PTFE membranes (Gore-Tex TR9, W. L. Gore & Associates Inc.) were applied in the control group, and titanium-reinforced d-PTFE membranes (Cytoplast TI250XL, Osteogenics Biomedical Inc.) were used in the test sites (Figs 1 and 2).

The membrane was adapted and stabilized lingually with fixation pins (Maxil Micro-pins, Omnia, Fidenza, Italy). Then a graft composed of autologous bone (harvested with a scraper) and mineralized bone allograft (Puros, Zimmer Dental, Carlsbad, CA, USA) in 50 : 50 proportion was positioned around the implants, completely filling the defect (Figs 3 and 4). Finally, the membrane was also stabilized on the buccal side with two or more fixation pins to ensure a complete and stable coverage of the grafted area.

Then, the mucoperiosteal flaps were tested for their passivity and displacement capability, and they were adapted to completely cover the augmentation area without tension. A double line of sutures was performed. At first, horizontal mattress sutures were carried out

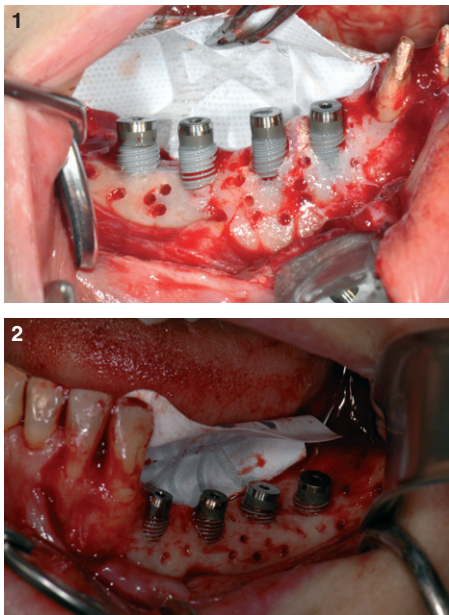


Fig. 1 and 2. Implants were inserted in the programmed position and left protruding from the alveolar crest for the planned amount of vertical regeneration. Dense polytetrafluoroethylene (D-PTFE) (Fig. 1) and expanded polytetrafluoroethylene (e-PTFE) (Fig. 2) membranes were fixed to the bone with pins on the lingual side, and multiple cortical perforations were performed.

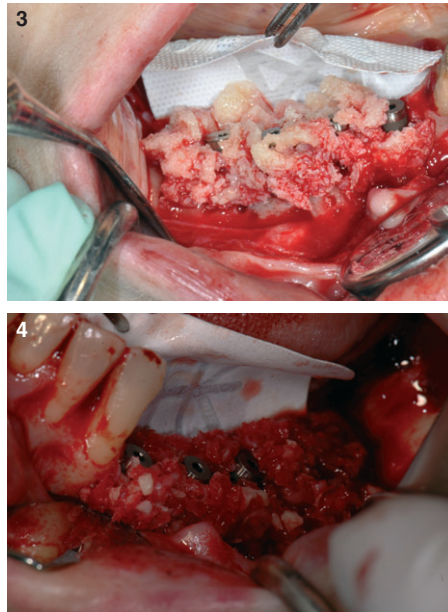


Fig. 3 and 4. A graft composed of autologous bone and mineralized bone allograft in 50 : 50 proportion was positioned around the implants, filling completely the defect, either in test (Fig. 3) or in control group (Fig. 4).

to obtain a close contact between the inner connective portions of the flaps; then, the closure was completed with multiple interrupted sutures (Gore-Tex CV5, W.L. Gore & Associates Inc., or Cytoplast CS0518, Osteogenics Biomedical Inc.). Amoxicillin/clavulanate potassium (875 + 125 mg) tablets (Augmentin, GlaxoSmithKline, Brentford, UK), one tablet twice a day, and ibuprofen (600 mg) (Brufen, Abbott Laboratories, Abbott Park, IL, USA), twice a day, were prescribed for 1 week. Patients were also instructed to rinse twice a day with a 0.2% chlorhexidine solution and to avoid mechanical plaque removal in the surgical area until the sutures were present. Sutures were removed 14 days after surgery. Postsurgical visits were scheduled at 15-day intervals to check the course of healing.

#### Intrasurgical measurements

Vertical bone variations were evaluated with measurements taken at first surgery and at membrane removal. At both stages, the vertical component of the defect was recorded with a periodontal probe by measuring the distance between the top of the implant shoulder and the first visible bone-implant contact (distance implant bone, DIB) on the mesial and distal aspects of each fixture (Buser et al. 1991; Weber et al. 1992).

#### Biopsy retrieval and histological analysis

At second-stage surgery, biopsies were retrieved in areas where it was necessary to place additional implants, not inserted during

augmentation procedures due to lack of primary stability. For ethical reasons, regenerated tissue retrieval was limited to these cases. Biopsies were collected using a trephine bur with an inner diameter of 2 mm (Medesy, Maniago, Italy), while performing implant site preparations.

The bone biopsies were immediately rinsed in saline, fixed in 10% neutral buffered formalin, and processed to obtain thin ground sections. The specimens were dehydrated in an ascending series of alcohol rinses and then embedded in Remacryl resin. (Remacryl is an experimental resin prepared by Mr. Cesare Scala, Istituto di Microscopia Elettronica Clinica, Ospedale Sant'Orsola, Bologna, Italy.) After polymerization, the specimens were sectioned at 200–250  $\mu$ m by a high-speed rotating blade microtome (Micromet, Remet, Bologna, Italy) and ground down to about 40–50  $\mu$ m by a grinding machine (LS2, Remet). The histological slides were routinely stained with toluidine blue and basic fuchsin solutions. For the tetracycline label analysis, a special UV filter applied to a Zeiss Axioscop light microscope was used.

#### Statistical analysis

All data were transferred into a single electronic dataset, and all analyses were performed using R Software version 2.12.2 (R Foundation for Statistical Computing, Wien, Austria). The statistical independent unit is the patient. Data are expressed as mean  $\pm$  standard deviation, and a mixed model was selected to evaluate differences between the test and the control sites. The level of significance was set at 5%.

## Results

#### Clinical results

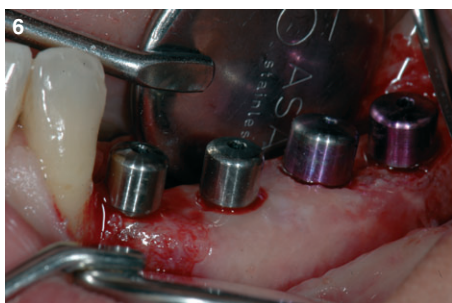
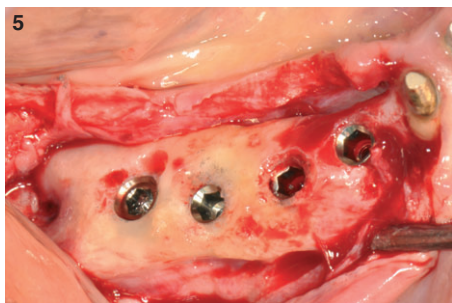
In 23 consecutive patients, 26 mandibular sites were treated with the insertion of 78 dental implants associated with contextual vertical guided bone regeneration procedures. No dropouts presented during the entire period of observation. In accordance with Fontana et al. (2011), surgical and healing complications were recorded. Minor temporary neurological complications (class B) occurred in three cases: paresthesia caused by stretching of mental nerve fibers during flap management or edema compression on the mandibular nerve. The timing for a complete healing of the injured nerves varied between 1 week and 4 weeks. Minor vascular complications (class C) also occurred, leading to various grades of local edema or hematoma

caused by buccal periosteal incisions and detachment of the mucosal attachment of the mylohyoid muscle on the lingual side. These vascular complications were expected by the surgeon, as this technique needs periosteal incisions to obtain an adequate passivation of the flap. No other surgical or healing complications occurred. The postoperative period was uneventful in all 26 sites, and no evidence of local or systemic side effects (membrane exposures and/or infections, hemorrhagic problems and neurosensory changes) was observed in any patient throughout the study. The membranes were removed after a healing period of 6–7 months (average 25.6 weeks ± 3.8), and the implants were connected with healing abutments. The membrane removal procedure was easier to perform in the d-PTFE group than the e-PTFE group. In all sites, the bone crest level had increased, and the vertical defects around the implants were satisfactorily filled with a newly formed hard tissue in both groups (Figs 5 and 6). In some of the sites, a thin fibrous tissue layer (<1 mm) was present between the membrane and the regenerated bone-like tissue. Clinical results are summarized in Table 1.

In the test group (d-PTFE), the implants were left to protrude 0–8 mm from the crest to achieve vertical bone regeneration. A comparison between mean bone defect around implants at baseline (4.70 mm, SD ± 1.69)

**Table 1.** Intrasurgical measurements of vertical bone gain

Patient	Implant site	Vertical defect at first surgery (mm)		Membrane healing (weeks)	Vertical defect at membrane removal (mm)		Vertical bone gain (mm)	
		Mesial	Distal		Mesial	Distal	Mesial	Distal
<b>Test group (Cytoplast)</b>								
R.L.	35	1.0	8.0	25	0.0	2.5	1.0	5.5
	36	7.0	5.5	25	0.0	0.0	7.0	5.5
	37	4.5	4.0	25	-1.5	-1.5	6.0	5.5
E.B.	46	2.5	2.5	24	-1.5	-1.5	4.0	4.0
	47	2.5	2.5	24	-1.5	-1.5	4.0	4.0
M.B.	35	0.0	2.5	27	0.0	0.0	0.0	0.0
	36	5.0	7.0	27	0.0	0.0	5.0	7.0
	37	5.5	5.5	27	0.0	0.0	5.5	5.5
M.R.M.	45	0.0	4.0	23	0.0	0.0	0.0	4.0
	46	6.0	6.0	23	-1.0	-1.0	7.0	7.0
	47	4.5	4.0	23	-1.5	-1.5	6.0	5.5
L.C.	36	5.5	6.5	24	-0.5	-0.5	6.0	7.0
	37	5.0	4.5	24	-1.5	-1.5	6.5	6.0
	46	5.5	6.5	24	-1.0	-1.0	6.5	7.5
	47	4.5	4.5	24	-1.0	-1.0	5.5	5.5
A.D.	34	0.0	6.0	24	-1.0	-1.0	1.0	7.0
	35	5.5	5.5	24	-1.0	0.0	6.5	5.5
	36	6.0	6.5	24	-1.0	0.0	7.0	6.5
	37	6.5	6.5	24	-1.5	-1.5	8.0	8.0
C.D.	43	1.0	2.5	29	-1.0	-1.0	2.0	3.5
	44	3.0	5.0	29	0.0	0.0	3.0	5.0
	46	5.5	6.0	29	-1.0	-1.0	6.5	7.0
	47	5.0	5.0	29	-1.5	-1.5	6.5	6.5
V.B.	35	2.5	5.5	24	0.0	0.0	2.5	5.5
	36	6.0	6.0	24	0.0	0.0	6.0	6.0
	37	4.5	4.0	24	-1.5	-1.5	6.0	5.5
M.C.	44	1.0	2.5	23	-1.5	-1.5	2.5	4.0
	45	3.0	3.0	23	-1.5	-1.5	4.5	4.5
	46	3.0	2.5	23	-1.5	-1.5	4.5	4.0
A.S.	35	1.5	6.0	24	0.0	0.0	1.5	6.0
	36	6.0	6.0	24	0.0	0.0	6.0	6.0
	37	5.0	4.0	24	-1.5	-1.5	6.5	5.5
A.I.	35	0.0	8.0	25	0.0	0.0	0.0	8.0
	36	5.5	6.5	25	-1.0	-1.0	6.5	7.5
	37	6.0	5.5	25	-1.5	-1.5	7.5	7.0
A.B.	45	0.0	6.0	24	0.0	0.0	0.0	6.0
	46	5.0	6.0	24	0.0	-1.0	5.0	7.0
	47	2.5	2.5	24	-1.5	-1.5	4.0	4.0
<b>Control group (Gore-Tex)</b>								
B.F.	34	1.0	5.0	28	0.0	0.0	1.0	5.0
	35	6.5	6.5	28	0.0	0.0	6.5	6.5
	36	7.5	6.5	28	0.0	0.0	7.5	6.5
A.M.G.	35	1.0	2.5	29	-1.5	-1.5	2.5	4.0
	36	0.0	2.5	29	-1.5	-1.5	1.5	4.0
	37	4.5	2.5	29	-1.5	-1.5	6.0	4.0
M.G.	36	3.0	3.5	23	-1.5	-1.5	4.5	5.0
	37	3.5	3.5	23	-1.5	-1.5	5.0	5.0
D.G.	34	0.0	4.5	24	0.0	0.0	0.0	4.5
	35	3.5	3.5	24	0.0	0.0	3.5	3.5
	36	3.5	3.0	24	-1.5	-1.5	5.0	4.5
	37	4.5	4.5	24	-1.5	-1.5	6.0	6.0
G.P.	46	5.0	4.5	28	-1.5	-1.5	6.5	6.0
	47	1.0	0.0	28	-1.5	-1.5	2.5	1.5
	45	0.0	1.5	28	0.0	0.0	0.0	1.5
	46	4.0	7.0	28	0.0	0.0	4.0	7.0
E.B.	47	5.5	5.5	28	-1.0	-1.0	6.5	6.5
	35	1.0	3.0	24	0.0	0.0	1.0	3.0
	36	5.0	5.5	24	0.0	0.0	5.0	5.5
R.T.	37	4.5	4.0	24	-1.5	-1.5	6.0	5.5
	44	1.0	8.0	23	0.0	0.0	1.0	8.0
	45	6.5	6.5	23	0.0	0.0	6.5	6.5
	46	6.0	8.0	23	0.0	0.0	6.0	8.0
	47	5.0	5.0	23	0.0	0.0	5.0	5.0
	34	0.0	0.0	29	0.0	0.0	0.0	0.0
	35	1.5	2.5	29	0.0	0.0	1.5	2.5
36	5.5	5.5	29	0.0	0.0	5.5	5.5	
37	6.5	7.5	29	0.0	0.0	6.5	7.5	



**Fig. 5 and 6.** At membrane removal, vertical defects around the implants were satisfactorily filled with newly formed hard tissue in both groups (dense polytetrafluoroethylene (d-PTFE) in Fig. 5; expanded polytetrafluoroethylene (e-PTFE) in Fig. 6).

Table 1. (continued)

Patient	Implant site	Vertical defect at first surgery (mm)		Membrane healing (weeks)	Vertical defect at membrane removal (mm)		Vertical bone gain (mm)	
		Mesial	Distal		Mesial	Distal	Mesial	Distal
Control group (Gore-Tex)								
M.T.	34	0.0	2.5	28	0.0	0.0	0.0	2.5
	35	4.5	3.5	28	-1.5	-1.5	6.0	5.0
	36	3.5	2.5	28	-1.5	-1.5	5.0	4.0
	37	3.5	2.5	28	-2.0	-2.0	5.5	4.5
M.L.S.	45	0.0	1.5	28	0.0	0.0	0.0	1.5
	46	5.0	3.0	28	-1.5	-1.5	6.5	4.5
	47	6.0	5.5	28	-1.5	-1.5	7.5	7.0
G.F.	45	1.5	1.5	24	-1.5	-1.5	3.0	3.0
	46	2.5	4.0	24	-1.5	-1.5	4.0	5.5
	47	4.0	2.5	24	-1.5	-1.5	5.5	4.0
G.G.	36	1.5	5.5	29	-1.0	-1.0	2.5	6.5
	37	5.5	5.0	29	-1.0	-1.0	6.5	6.0

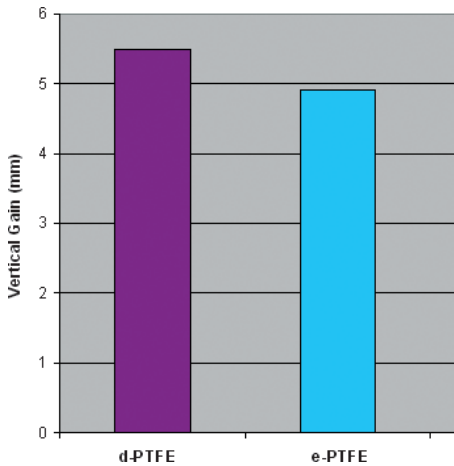


Fig. 7. Mean vertical bone gain in test and control groups at membrane removal.

and at membrane removal (-0.80 mm, SD ± 0.76) showed a mean vertical bone regeneration of 5.49 mm (SD ± 1.58). In the

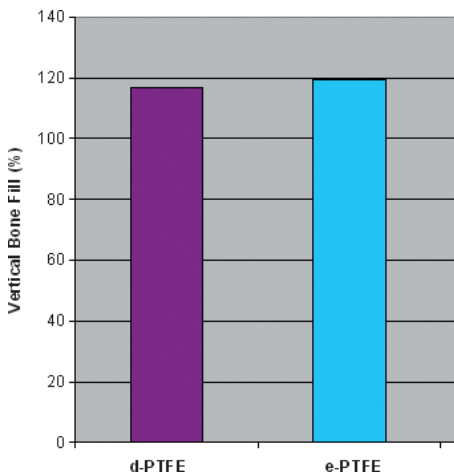


Fig. 8. Percentage of vertical bone gain at membrane removal related to baseline bone level in test and control groups.

control group (e-PTFE), the implants were also left to protrude 0–8 mm from the crest. The mean bone defect recorded at baseline was 4.10 mm (SD ± 1.86), while at membrane removal, it was -0.81 mm (SD ± 0.74), with a mean vertical bone gain of 4.91 mm (SD ± 1.78). Mean initial defect and mean vertical bone gain were not significantly different in the test group and in the control group (*P* = NS). Vertical bone gain in the two groups is summarized in Fig. 7. The percentage of vertical bone defect filling against baseline bone level in test and control groups was 116.8% and 119.7%, respectively (*P* = NS) (Fig. 8). Due to the limited numerosity of the sample, it was not possible to use stratifying factors (i.e., smoke, gender, age).

All 78 implants appeared clinically stable and were subsequently loaded with cemented ceramic crowns. At last follow-up visit (15–37 months from the membrane removal), all the implants were functioning satisfactorily.

**Histological observations**

A total of two biopsies were collected at the time of membrane removal (one sample each in control and test groups), demonstrating bone with different degrees of maturation, density, and structure (Fig. 9). In the examined biopsies, the morphologic analysis revealed no differences in the quality of the regenerated tissue between the test and the control group. Two main areas can be described in both specimens: an apical portion with well-organized lamellar bone, which can be classified as hard/dense bone (Rebaudi et al. 2010), with small lacunae hosting osteocytes and a coronal part, mainly characterized by woven or composite bone with the presence of small and immature trabeculae (Figs 10 and 11).



Fig. 9. This sample is representative of all cases because the same patterns were observed both in test and in control group. This biopsy was retrieved during implant site preparation, in the center of the regenerated crest, using a trephine drill. Two main areas can be described: an apical portion where native bone of the crest is still visible and a coronal portion where regenerated bone trabeculae around grafting material are evident.

Lamellar bone seen in the apical part represents the native mature bone of the mandibular crest, which does not change its original structure and does not show extensive remodeling activity. The trabecular bone seen in the coronal part represents the regenerated part of the biopsy. This bone can be classified as soft bone (Rebaudi et al. 2010), and it was mainly composed of thin composite or woven bone trabeculae. Bone trabeculae of the coronal part are often in contact with granules of grafting material, which are surrounded by newly formed bone or distributed in marrow spaces. In several fields, it is possible to observe osteocytes in their mineralized

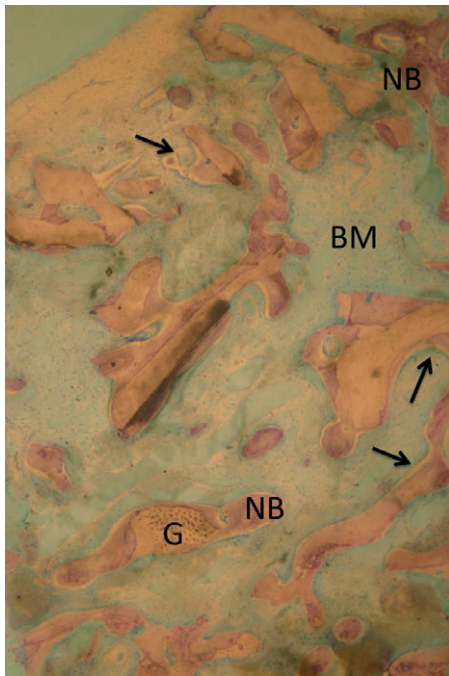


Fig. 10. In the coronal area, observation of bone marrow tissue (BM) revealed particles of the graft material (G) well integrated and in contact with newly formed bone trabeculae (NB). Some bone trabeculae are covered by osteoid layers (arrowheads).

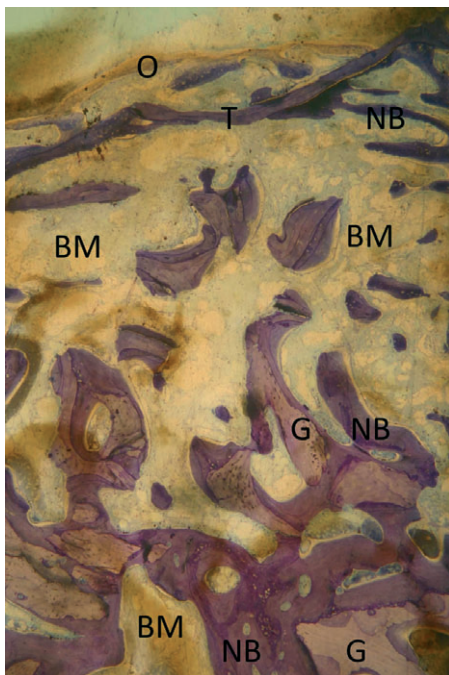


Fig. 11. In the coronal area (stained with toluidine blue and basic fuchsin), it is possible to observe the presence of a thin continuous bone trabecula (T) covering the entire regenerated area. Coronally to this trabecula, some small, immature trabeculae of woven bone are visible, covered by a continuous layer of osteoid (O). Apically, it is possible to observe particles of the graft (G), which are surrounded and in contact with newly formed bone trabeculae (NB), in the context of the bone marrow tissue (BM).

matrix, signs of angiogenesis, and the formation of a few osteonic structures. Some of the granules not in contact with bone trabeculae show macrophages wedged into niches, a clear sign of resorption of the graft particles. It was not possible to observe newly formed cortical bone with a periosteum covering regenerated bone, but only a thin horizontal trabecula, delimited by a continuous layer of osteoid covered by osteoblasts which seemed to form new bone. No acute inflammatory infiltrate and no evidence of anomalous tissue reactions were present.

## Discussion

Expanded polytetrafluoroethylene is considered the gold standard of non-resorbable membranes in vertical GBR. E-PTFE membrane is a chemically stable and biologically inert polymer, featuring a porous structure and flexible form. It shows resistance to microbiological and enzymatic degradation and does not stimulate immunological reactions (Becmeur et al. 1990). E-PTFE membrane consists of two different parts: an open microstructure portion (100–300  $\mu\text{m}$  porosity) and an occlusive portion (<8  $\mu\text{m}$  porosity). The open microstructure promotes an ingrowth of collagen fibrils on its surface, enhancing membrane stability, and allows for the diffusion of nutrients through the pores. The occlusive portion, on the contrary, is relatively impermeable to fluids and completely blocks out the migration of soft tissue cells into the area of bone growth.

For these reasons, some authors have regarded the presence of a porous portion in barrier materials as an important factor in achieving satisfactory results in regenerative therapy (Dahlin et al. 1988; Scantlebury 1994). On the other hand, other experimental studies also demonstrated complete bone regeneration, but using totally occlusive barrier devices (Kostopoulos et al. 1994; Schmid et al. 1994; Polimeni et al. 2004). Both Zellin & Linde (1996) and Lundgren et al. (1998) reported that porous membranes significantly enhanced new bone formation during the initial healing period, compared with non-porous devices. However, after 12 weeks of healing, similar amounts of regenerated bone were observed when using all types of barriers, irrespective of porosity. In an interesting pilot study with prototype e-PTFE membranes, Simion et al. (1999) found that an experimental barrier with an extremely open outer microstructure, in combination with a totally occlusive inner portion, demonstrated

the most favorable biologic response, but it was not clinically manageable as a result of difficulties in membrane removal. Based on these observations, although the presence of a porous portion on a membrane seems to play an important role in the stabilization of the device, favoring its integration with the soft tissues, it does not appear to be essential in obtaining bone regeneration.

Dense polytetrafluoroethylene membrane does not have a porous structure, and its integration is weak, even though it presents a textured surface, enhancing its stability in the tissues. While this characteristic makes possible an easy removal at second-stage surgery, it still requires special care and attention during its positioning and stabilization. In fact, membrane stability remains a fundamental prerequisite for success in GBR, which must be obtained with appropriate fixation devices (pins or screws) to ensure the absence of micromovements (Dahlin et al. 1998). Moreover, the absence of a porous structure does not allow fluids and nutrients from the overlying periosteal vessels to pass through the membrane, thus increasing the importance of performing multiple perforations of the cortical bone to enhance blood supply to the augmented area (Frost 1983; Nishimura et al. 2004).

Furthermore, it is well established that the presence of a porous portion is a condition favoring the accumulation of bacterial biofilm. Specifically, a surface roughness from 10 to 100  $\mu\text{m}$  promotes adhesion of bacteria because air entrapped in rough areas initiates protein and cell adhesion (Merrill 1987). Thus, in case of exposure to the oral environment, bacterial penetration from the outer to the inner surface of an e-PTFE membrane is unavoidable and always occurs within 4 weeks (Selvig et al. 1990; Simion et al. 1994b). In contrast, the low porosity (<0.3  $\mu\text{m}$ ) of d-PTFE membrane prevents cell adhesion and is less prone to the incorporation of bacteria into its structure. For example, human studies on socket preservation with d-PTFE membranes, which were left intentionally exposed, documented promising clinical and histological results in terms of regeneration without signs of infection (Barthee 2001; Barber et al. 2007; Barboza et al. 2010). Nevertheless, in our study, the membranes were covered by tension-free flaps, and the occurrence of exposure was not observed in either test or control groups.

From a clinical point of view, the results of this randomized controlled trial suggest that d-PTFE membranes can be successfully used for GBR procedures in vertical ridge augmentation

of atrophic mandibular ridges, as documented by the similarity of defect resolution in the test sites compared with controls treated with e-PTFE membranes. Mean vertical bone gain obtained in the test group (5.49 mm [SD  $\pm$  1.58]) was not significantly different from the control group (4.91 mm [SD  $\pm$  1.78]), even if it should be noted that the mean initial defect was slightly greater in the test group (4.70 mm [SD  $\pm$  1.69]) than in the controls (4.10 mm [SD  $\pm$  1.86]) ( $P = \text{NS}$ ). Therefore, also the normalized data (percentage changes against baseline) do not show any statistically significant difference between test and control groups (test sites 116.8%; control sites 119.7% –  $P = \text{NS}$ ).

After 6 months of healing, the present study showed histologically that it was not possible to detect differences in regenerated

tissue quality between the two groups. This is consistent with other clinical studies on vertical bone regeneration performed using non-resorbable or resorbable barriers and various osteoconductive biomaterials (Zitzmann et al. 1997; Jung et al. 2003, 2009; Simion et al. 2007). However, histological observations were only performed on two samples, one for each group. For this reason, these results might be considered as merely descriptive, encouraging future studies focusing on the histological aspect in a more systematic way.

In conclusion, within the limitations of this study, no clinical or histological differences in vertical bone gain around implants were observed, while performing GBR procedures with either e-PTFE or d-PTFE membranes. The observation of an easier removal

of the membrane and the possible easier management of membrane exposures could support the use of d-PTFE membranes for vertical ridge augmentation of atrophic ridges by means of GBR techniques. Nevertheless, further clinical and histological studies are necessary to confirm our findings and to evaluate long-term results in terms of implant survival and stability of the vertically augmented bone.

**Acknowledgements:** The authors wish to thank the histological laboratory of Dr. Paolo Trisi, Pescara, Italy, for the histological analysis of the samples, Mrs. Gabriella Tomasina for her valuable help and BioCRA (Biomaterials Clinical-Histological Research association) for the support.

## References

- Aghaloo, T.L. & Moy, P.K. (2008) Which hard tissue augmentation techniques are the most successful in furnishing bony support for implant placement? *International Journal of Oral & Maxillofacial Implants* **22**: 49–70.
- Barber, H.D., Lignelli, J., Smith, B.M. & Barteel, B.K. (2007) Using a dense PTFE membrane without primary closure to achieve bone and tissue regeneration. *Journal of Oral and Maxillofacial Surgery* **65**: 748–752.
- Barboza, E.P., Stutz, B., Ferreira, V.F. & Carvalho, W. (2010) Guided bone regeneration using nonexpanded polytetrafluoroethylene membranes in preparation for dental implant placements. A report of 420 cases. *Implant Dentistry* **19**: 2–7.
- Barteel, B.K. (1998) Evaluation of a new polytetrafluoroethylene guided tissue regeneration membrane in healing extraction sites. *Compendium of Continuing Education in Dentistry* **19**: 1256–1264.
- Barteel, B.K. (2001) Extraction site reconstruction for alveolar ridge preservation. Part 2: membrane-assisted surgical technique. *Journal of Oral Implantology* **27**: 194–197.
- Becmeur, F., Geiss, S., Laustrat, S., Bientz, J., Marcellin, L. & Sauvage, P. (1990) History of teflon. *European Urology* **17**: 299–300.
- Buser, D., Weber, H.P., Bragger, U. & Balsiger, C. (1991) Tissue integration of one-stage ITI implants. 3-year results of a longitudinal study with Hollow-Cylinder and Hollow-Screw implants. *International Journal of Oral and Maxillofacial Implants* **6**: 405–412.
- Carpio, L., Loza, J., Lynch, S. & Genco, R. (2000) Guided bone regeneration around endosseous implants with anorganic bovine bone mineral. A randomized controlled trial comparing bioabsorbable versus non-resorbable barriers. *Journal of Periodontology* **71**: 1743–1749.
- Dahlin, C., Linde, A., Gottlow, J. & Nyman, S. (1988) Healing of bone defects by guided tissue regeneration. *Plastic and Reconstructive Surgery* **81**: 672–676.
- Dahlin, C., Simion, M., Nanmark, U. & Sennerby, L. (1998) Histological morphology of the e-PTFE/tissue interface in humans subjected to guided bone regeneration in conjunction with oral implant treatment. *Clinical Oral Implants Research* **9**: 100–106.
- Fontana, F., Maschera, E., Rocchietta, I. & Simion, M. (2011) Clinical classification of complications in guided bone regeneration procedures by means of a nonresorbable membrane. *International Journal of Periodontics and Restorative Dentistry* **31**: 265–273.
- Fotek, P.D., Neiva, R.F. & Wang, H.L. (2009) Comparison of dermal matrix and polytetrafluoroethylene membrane for socket bone augmentation: a clinical and histologic study. *Journal of Periodontology* **80**: 776–785.
- Frost, H.M. (1983) The regional acceleratory phenomenon: a review. *Henry Ford Hospital Medical Journal* **31**: 3–9.
- Hammerle, C.H. & Jung, R.E. (2003) Bone augmentation by means of barrier membranes. *Periodontology* **2000** **33**: 36–53.
- Hoffmann, O., Barteel, B.K., Beaumont, C., Kasaj, A., Deli, G. & Zafropoulos, G.G. (2008) Alveolar bone preservation in extraction sockets using non-resorbable dPTFE membranes: a retrospective non-randomized study. *Journal of Periodontology* **79**: 1355–1369.
- Jung, R.E., Glauser, R., Scharer, P., Hammerle, C.H.F. & Weber, F.E. (2003) The effect of rhBMP-2 on guided bone regeneration in humans. A randomized, controlled clinical and histomorphometric study. *Clinical Oral Implants Research* **14**: 556–568.
- Jung, R.E., Halg, G.A., Thoma, D.S. & Hammerle, C.H.F. (2009) A randomized, controlled clinical trial to evaluate a new membrane for guided bone regeneration around dental implants. *Clinical Oral Implants Research* **20**: 162–168.
- Karring, T., Nyman, S., Gottlow, J. & Laurell, L. (1993) Development of the biological concept of guided tissue regeneration—animal and human studies. *Periodontology* **2000** **1**: 26–35.
- Kostopoulos, L., Karring, T. & Uruguchi, R. (1994) Formation of jawbone tuberosities by guided tissue regeneration. An experimental study in the rat. *Clinical Oral Implants Research* **5**: 245–253.
- Lamb, J.W., 3rd, Greenwell, H., Drisko, C., Henderson, R.D., Scheetz, J.P. & Rebitski, G. (2001) A comparison of porous and non-porous teflon membranes plus demineralized freeze-dried bone allograft in the treatment of class II buccal/lingual furcation defects: a clinical reentry study. *Journal of Periodontology* **72**: 1580–1587.
- Llambes, F., Silvestre, F.J. & Caffesse, R. (2007) Vertical guided bone regeneration with bioabsorbable barriers. *Journal of Periodontology* **78**: 2036–2042.
- Lundgren, A., Lundgren, D. & Taylor, A. (1998) Influence of barrier occlusiveness on guided bone augmentation. An experimental study in the rat. *Clinical Oral Implants Research* **9**: 251–260.
- Merrill, E.W. (1987) Distinctions and correspondences among surfaces containing blood. *Annals of the New York Academy of Sciences* **516**: 196–203.
- Nishimura, I., Shimizu, Y. & Ooya, K. (2004) Effects of cortical bone perforation on experimental guided bone regeneration. *Clinical Oral Implants Research* **15**: 293–300.
- Parma-Benfenati, S., Tinti, C., Albrektsson, T. & Johansson, C. (1999) Histologic evaluation of guided vertical ridge augmentation around implants in humans. *International Journal of Periodontics and Restorative Dentistry* **19**: 424–437.
- Polimeni, G., Koo, K.T., Qahash, M., Xiropaidis, A.V., Albandar, J.M. & Wikesjo, U.M. (2004) Prognostic factors for alveolar regeneration: effect of tissue occlusion on alveolar bone regeneration with guided tissue regeneration. *Journal of Clinical Periodontology* **31**: 730–735.
- Preti, G., Martinasso, G., Peirone, B., Navone, R., Manzella, C., Muzio, G., Russo, C., Canuto, R.A. & Schierano, G. (2007) Cytokines and growth fac-

- tors involved in the osseointegration of oral titanium implants positioned using piezoelectric bone surgery versus a drill technique: a pilot study in minipigs. *Journal of Periodontology* **78**: 716–722.
- Proussaefs, P., Lozada, J., Kleinman, A., Rohrer, M.D. & McMillan, P.J. (2003) The use of titanium mesh in conjunction with autogenous bone graft and inorganic bovine bone mineral (Bio-Oss) for localized alveolar ridge augmentation: a human study. *International Journal of Periodontics and Restorative Dentistry* **23**: 185–195.
- Rebaudi, A., Trisi, P., Cella, R. & Cecchini, G. (2010) Preoperative evaluation of bone quality and bone density using a novel CT/microCT-based hard-normal-soft classification system. *International Journal of Oral and Maxillofacial Implants* **25**: 75–85.
- Ronda, M. & Stacchi, C. (2011) Management of a coronally advanced lingual flap in regenerative osseous surgery: a case series introducing a novel technique. *International Journal of Periodontics and Restorative Dentistry* **31**: 505–513.
- Scantlebury, T.V. (1994) Bone regeneration: biological basis. In: Buser, D., Dahlin, C. & Schenk, R., eds. *Guided Bone Regeneration in Implant Dentistry*, 49–100. Chicago: Quintessence Publ. Inc.
- Schaeren, S., Jaquiéry, C., Heberer, M., Tolnay, M., Vercellotti, T. & Martin, I. (2008) Assessment of nerve damage using a novel ultrasonic device for bone cutting. *Journal of Oral and Maxillofacial Surgery* **66**: 593–596.
- Schmid, J., Hämmerle, C.H.F., Olah, A.J. & Lang, N.P. (1994) Membrane permeability is unnecessary for guided generation of new bone. An experimental study in the rabbit. *Clinical Oral Implants Research* **5**: 125–130.
- Selvig, K.A., Nilveus, R.E., Fitzmorris, L., Kersten, B. & Khorsandi, S.S. (1990) Scanning electron microscopic observations of cell populations and bacterial contamination of membranes used for guided periodontal tissue regeneration in humans. *Journal of Periodontology* **61**: 515–520.
- Simion, M., Dahlin, C., Blair, K. & Schenk, R.K. (1999) Effect of different microstructures of e-PTFE membranes on bone regeneration and soft tissue response: a histologic study in canine mandible. *Clinical Oral Implants Research* **10**: 73–84.
- Simion, M., Fontana, F., Rasperini, G. & Maiorana, C. (2007) Vertical ridge augmentation by expanded-polytetrafluoroethylene membrane and a combination of intraoral autogenous graft and deproteinized anorganic bovine bone (Bio Oss). *Clinical Oral Implants Research* **18**: 620–629.
- Simion, M., Jovanovic, S.A., Tinti, C. & Parma-Benfenati, S. (2001) Long term evaluation of osseointegrated implants inserted at the time or after vertical ridge augmentation. A retrospective study on 123 implants with 1–5 year follow up. *Clinical Oral Implants Research* **12**: 35–45.
- Simion, M., Jovanovic, S.A., Trisi, P., Scarano, A. & Piattelli, A. (1998) Vertical ridge augmentation around dental implants using a membrane technique and autogenous bone or allografts in humans. *International Journal of Periodontics and Restorative Dentistry* **18**: 8–23.
- Simion, M., Trisi, P., Maglione, M. & Piattelli, A. (1994b) A preliminary report on a method for studying the permeability of expanded polytetrafluoroethylene membrane to bacteria in vitro: a scanning electron microscopic and histological study. *Journal of Periodontology* **65**: 755–761.
- Simion, M., Trisi, P. & Piattelli, A. (1994a) Vertical ridge augmentation using a membrane technique associated with osseointegrated implants. *International Journal of Periodontics and Restorative Dentistry* **14**: 496–511.
- Stacchi, C., Vercellotti, T., Torelli, L., Furlan, F. & Di Lenarda, R. (2013) Changes in implant stability using different site preparation techniques: twist drills versus Piezosurgery. A single-blinded, randomized, controlled clinical trial. *Clinical Implant Dentistry and Related Research* **15**: 188–197.
- Tinti, C. & Parma-Benfenati, S. (1998) Vertical ridge augmentation: surgical protocol and retrospective evaluation of 48 consecutively inserted implants. *International Journal of Periodontics and Restorative Dentistry* **18**: 434–443.
- Tinti, C., Parma-Benfenati, S. & Polizzi, G. (1996) Vertical ridge augmentation: what is the limit? *International Journal of Periodontics and Restorative Dentistry* **16**: 220–229.
- Walters, S.P., Greenwell, H., Hill, M., Drisko, C., Pickman, K. & Scheetz, J.P. (2003) Comparison of porous and non-porous teflon membranes plus a xenograft in the treatment of vertical osseous defects: a clinical reentry study. *Journal of Periodontology* **74**: 1161–1168.
- Weber, H., Buser, D., Fiorellini, J. & Williams, R. (1992) Radiographic evaluation of crestal bone levels adjacent to nonsubmerged titanium implants. *Clinical Oral Implants Research* **3**: 181–188.
- Zellin, G. & Linde, A. (1996) Effects of different osteopromotive membrane porosities on experimental bone neogenesis in rats. *Biomaterials* **17**: 695–702.
- Zitzmann, N.U., Naef, R. & Schärer, P. (1997) Resorbable versus nonresorbable membranes in combination with Bio-Oss for guided bone regeneration. *International Journal of Oral & Maxillofacial Implants* **12**: 844–852.
- Zitzmann, N.U., Schärer, P. & Marinello, C.P. (2001) Long-term results of implants treated with guided bone regeneration: a 5-year prospective study. *International Journal of Oral & Maxillofacial Implants* **16**: 355–366.

## Supporting Information

Additional Supporting Information may be found in the online version of this article:

**Data S1.** CONSORT 2010 checklist of information to include when reporting a randomised trial.\*



Copyright of Clinical Oral Implants Research is the property of Wiley-Blackwell and its content may not be copied or emailed to multiple sites or posted to a listserv without the copyright holder's express written permission. However, users may print, download, or email articles for individual use.